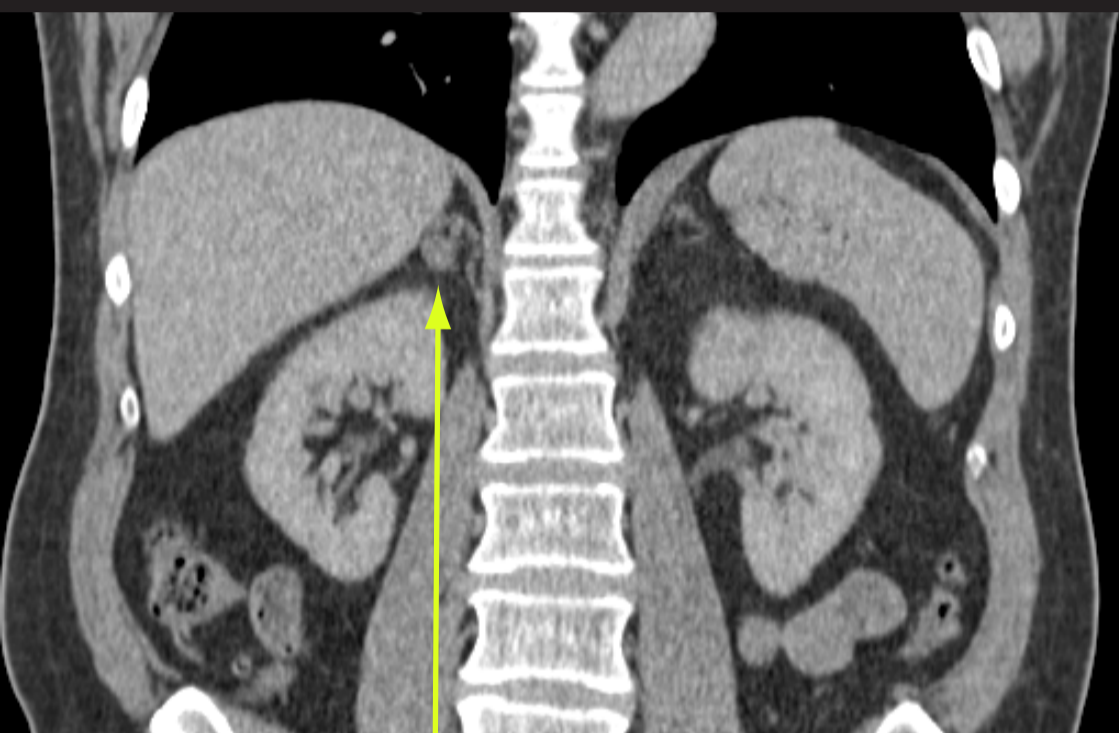


Conn's syndrome.

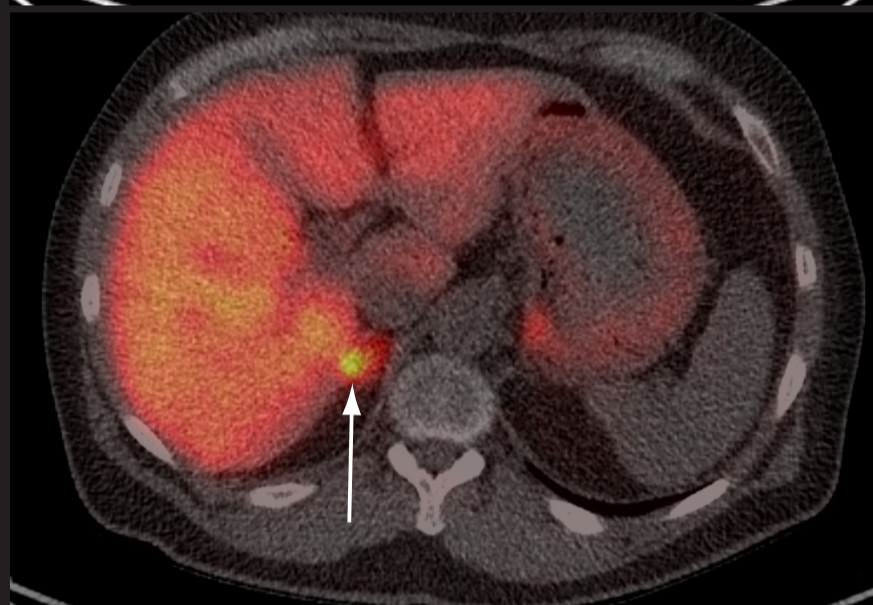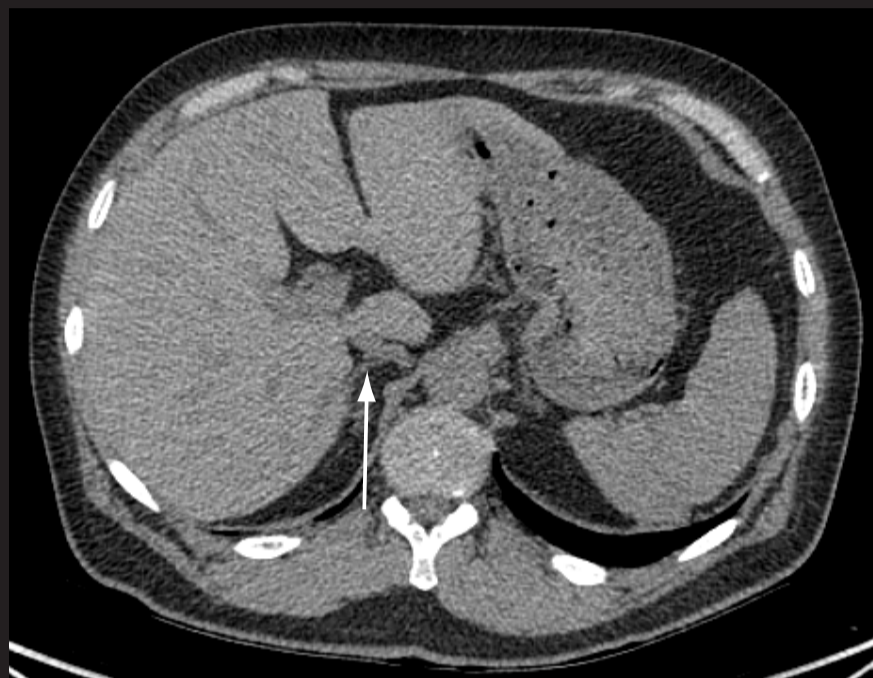A 50 year old hypertensive man was noted to have a low potassium (2.0mmol/L). Further investigation confirmed a raised aldosterone (1400). The axial and coronal CT images demonstrate a tumour in the right adrenal gland.

Uptake in the right adrenal of ^{11}C metomidate PET CT (right, lower) confirmed the presence of the adenoma responsible. The surgical specimen is shown at the bottom.

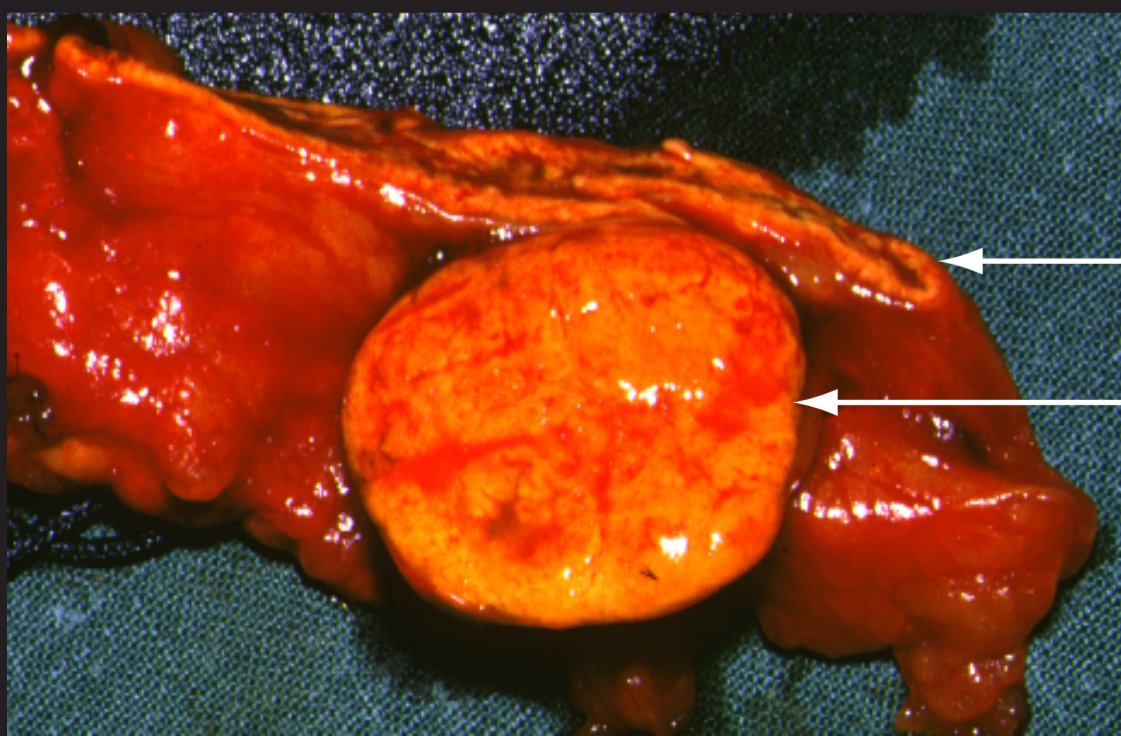
Coronal CT



Adrenal adenoma



^{11}C -metomidate PET CT scan



Normal adrenal cortex
("golden" colour)

Large Conn's adenoma